



**PATIENT**

Cali Vos

**SPECIES**

Canine

**BREED**

Chihuahua

**SEX**

Female Spayed

**AGE**

15.8 years

**WEIGHT**

14.8lbs

**INTERPRETED BY**

Maggie Machen Lamy,  
DVM, DACVIM  
(Cardiology)

**IMAGING PERFORMED BY**

Sammi Fuller, DVM

**HOSPITAL NAME**

Hart Family Veterinary  
Clinic

**REFERRING VET**

Dr. Fuller

**INVOICE**

46085

**DATE**

12/8/25

**PRESENTING CLINICAL SIGNS**

History: Grade 4/6 heart murmur. Persistent cough; didn't respond to Codeine. CXR showed cardiomegaly (VHS: 11.75) with concern for CHF. BP: 131mmHg. Started on Vetmedin 1.25mg BID and Furosemide 5mg BID.

**RADIOGRAPHIC FINDINGS** \*NOTE: Images submitted for supplemental cardiac information only.

Cardiomegaly; equivocal for CHF.

**ELECTROCARDIOGRAPHIC FINDINGS** \*Note: Single lead ECGs are evaluated as a rhythm strip.

Morphology/MEA cannot be definitively commented on.

A single lead ECG is available; 50mm/s. The average heart rate is 130bpm. The rhythm is sinus in origin, with a p for every QRS complex and vice versa. The P and QRS morphologies are positive.

No ectopic beats, pauses or other dysrhythmias observed.

ECG diagnosis: Normal sinus rhythm.

**ECHOCARDIOGRAM FINDINGS**

2D, m-mode, color flow and doppler imaging is available. The mitral valve is diffusely thickened with prolapse into the left atrial lumen. There is severe eccentric mitral regurgitation present. The MR velocity is normal. There is severe left atrial enlargement. There is mild left ventricular dilation. Left ventricular systolic function is hyperdynamic. Mild right atrial and ventricular dilation (subjective). Mild thickening of the tricuspid valve with trace TR. The aortic valve appears trileaflet with normal mobility. No significant AI. There is normal systolic flow velocity across the aortic valve. The main pulmonary artery is normal in diameter. The pulmonic valve is normal in appearance. Flow through the RVOT/PV is normal in velocity. Trace PI. No pericardial/pleural effusion or cardiac masses are seen.

**CARDIAC CHART**

CANINE CARDIAC PARAMETERS	MR VMAX (m/s)	TR VMAX (m/s)	LA/AO (Boon method)	LA/AO (Heart Base; Swe)	FS (%)	EF (%)	EPSS (cm)
NORMAL PARAMETER	4.5-5.5	<2.7	1.3	<1.6	28-40	40-100	<0.6
PATIENT	4.5	NM	NM	2.5	42	73	NM
CANINE CARDIAC PARAMETERS	HR (BPM)	AV VMAX (m/s)	PV MAX (m/s)	BODY WEIGHT (kg)	LA 2D short axis Base view (cm)	LVIDd Avg; 2D and m-mode short axis (cm)	LVIDs Avg; 2D and m-mode short axis (cm)
NORMAL PARAMETER	50-100	0.7-1.7	0.7-1.6	BELOW	BELOW	BELOW	BELOW
PATIENT	NM	1.3	0.6	6.7	3.0	3.9	2.3
*Normal chamber parameters expressed as a mean value (SD)							
<b>BODY WEIGHT DEPENDENT PARAMETERS</b>							
*Note: All measurements based upon multi-modal images and methods. An average value is reported.							
	3	1.27 (5.3)	2.46 (2.46)	1.36 (5.5)			
	5	1.40 (4.5)	2.74 (5.2)	1.60 (4.7)			
	10	1.50 (3.8)	3.27 (3.5)	2.06 (3.1)			
	15	1.83 (2.0)	3.71 (2.4)	2.43 (2.1)			
	20	2.02 (1.9)	4.14 (2.2)	2.80 (2.0)			
	25	2.18 (2.4)	4.48 (2.9)	3.10 (2.5)			
	30	2.33 (3.3)	4.83 (3.9)	3.39 (3.4)			
	35	2.48 (4.3)	5.17 (5.0)	3.69 (4.5)			
	40	2.62 (5.2)	5.48 (6.1)	3.96 (5.4)			
	50	2.88 (7.1)	6.07 (8.3)	4.46 (7.4)			

Adapted from June Boon, Veterinary Echocardiography, 1998  
Rishniw M and Hollis NE, J Vet Intern Med 2000; 14:429-435  
Hansson et al, Vet Rad and Ultrasound 2002  
Bonagura et al. Echocardiography: principles of interpretation, Vet Clin North Am 15:1177, 1995



## PATIENT

Cali Vos

## SPECIES

Canine

## BREED

Chihuahua

## SEX

Female Spayed

## AGE

15.8 years

## WEIGHT

14.8lbs

## INTERPRETED BY

Maggie Machen Lamy,  
DVM, DACVIM  
(Cardiology)

## IMAGING PERFORMED BY

Sammi Fuller, DVM

## HOSPITAL NAME

Hart Family Veterinary  
Clinic

## REFERRING VET

Dr. Fuller

## INVOICE

46085

## DATE

12/8/25

## INTERPRETATION OF THE FINDINGS & FURTHER RECOMMENDATIONS

The cause of the murmur is chronic degenerative valve disease causing severe mitral and trace tricuspid regurgitation. Severe left atrial enlargement indicates the risk for spontaneous congestive heart failure is elevated. Early pulmonary hypertension is suspected, which is likely secondary to chronic LA pressure elevation and active congestion. No additional issues are identified and the ECG is normal.

In light of the clinical signs, chest radiograph findings and severity of disease on echocardiogram, the diagnosis of congestive heart failure (stage C) is supported, and medications are warranted lifelong as below. Monitoring of sleeping respiratory rates will be paramount to screen for congestive heart failure at home. Cough suppression to improve QOL can also be considered (hydrocodone, 0.2-0.4mg/kg up to q4-6h PRN) for any residual mechanical cough in the face of normal sleeping respiratory rates. If able to be stabilized, the average survival time of canine patients with active pulmonary edema is 8-9 months on medications; however, most are able to maintain a good quality of life for that period on medications. Patient will always be at risk for recurrent CHF, development of arrhythmias/LA tear, syncope and/or sudden death in the future.

Omega fatty acid supplementation and mild salt restriction may also be of some long-term benefit. Monitor for acute progression of the cough, labored breathing, exercise intolerance or collapse episodes in the future.

**Elective anesthesia is not advised, as there is high risk for complication.** Risk: benefit ratio should be considered. Consider consultation with and/or referral to a facility with an anesthesiologist. Should you elect to proceed, cardiac protective drug choices (opioid/benzodiazepine premedication, propofol or alfaxalone induction, iso or sevoflurane gas) are recommended. Pre-oxygenate for 5-10 minutes prior to induction and recover in O2 cage. Monitor for arrhythmias, hypotension, and hypoxia both intra and post-operatively and intervene as necessary. Moderate IV fluid restriction is recommended to avoid fluid overload, while considering comorbidities, hydration status, BP, etc. Avoid heart rate stimulating drugs such as atropine unless clinically indicated.

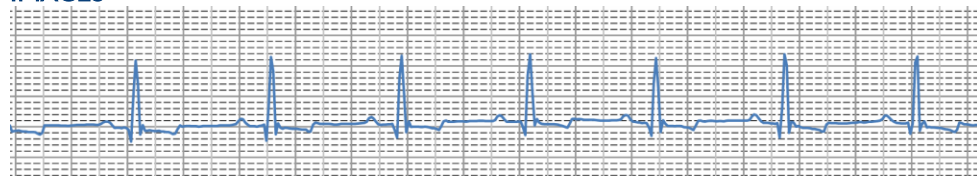
## PLAN

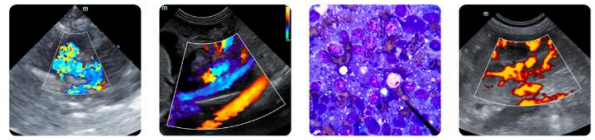
Continue Pimobendan 0.3mg/kg PO q12h. Continue Furosemide 1-2mg/kg PO q12h. Institute Spironolactone 1-2mg/kg PO q12h.

Monitor renal values and BP in 10-14 days, then every 3-4 months while on diuretics to ensure tolerance of medications. If doing well at home, renal values are reasonable and BP >130mmHg, administer ACEI 0.5mg/kg PO q12h. Consider hydrocodone if needed for QOL.

Recommend conservative monitoring with a recheck echocardiogram in 6 months, sooner if any development of associated clinical signs occurs in the interim.

## IMAGES





## PATIENT

Cali Vos

## SPECIES

Canine

## BREED

Chihuahua

## SEX

Female Spayed

## AGE

15.8 years

## WEIGHT

14.8lbs

## INTERPRETED BY

Maggie Machen Lamy,  
DVM, DACVIM  
(Cardiology)

## IMAGING PERFORMED BY

Sammi Fuller, DVM

## HOSPITAL NAME

Hart Family Veterinary  
Clinic

## REFERRING VET

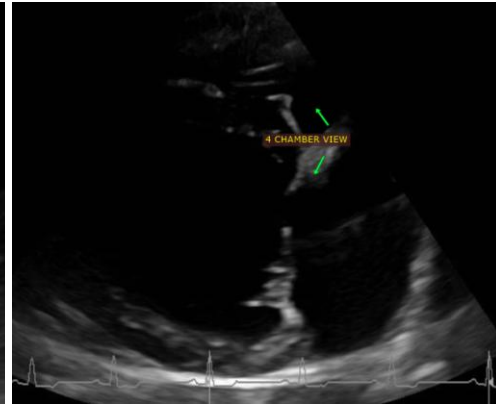
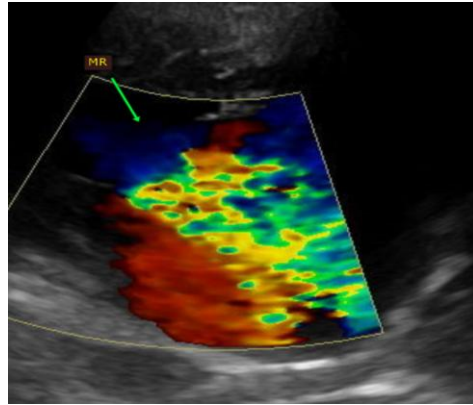
Dr. Fuller

## INVOICE

46085

## DATE

12/8/25



The information and recommendations provided are based on the images presented by the referring veterinarian. No evaluation can be communicated regarding pathology that was not visible in the image/video clips provided.

Thank you for this referral. This report was generated using transcription software, and minor dictation errors may be present. If the clinical or image interpretation does not parallel your findings or if I can be of any further assistance, please contact me.

Maggie Machen Lamy, DVM  
Diplomate of the American College of Veterinary Internal Medicine (Cardiology)  
info@sonopath.com